

areas of liquefactive necrosis (blurring of adjacent structures).

The posterior gastrostomy was left open and the intra-gastric trocars were removed, with closure of the anterior gastrostomies with polypropylene 0 extracorporeal Gea knots. A Jackson Pratt closed drain was placed in the subhepatic space. Surgery duration was 111 minutes, with intraoperative blood loss of 250 ml.

Oral diet was started the same day in the afternoon and the patient was released from the hospital with no complications, 48 h after the surgery.

## Ethical considerations

Before performing the surgical procedure, a written statement of informed consent was requested from the patient and the corresponding relative responsible for the patient, and observed by two witnesses. Because it is a case report, and not a research protocol, authorization by the ethics committee of the *Hospital General Dr. Manuel Gea González* was not required. The authors declare that this article contains no personal information of any kind that could identify the patients.

## Financial disclosure

No financial support was received in relation to this article.

## Conflict of interest

The authors declare that there is no conflict of interest.

## References

- Mathew MJ, Parmar AK, Sahu D, et al. Laparoscopic necrosectomy in acute necrotizing pancreatitis: our experience. *J Minim Access Surg.* 2014;10:126–31, <http://dx.doi.org/10.4103/0972-9941.134875>.
- Banks PA, Bollen TL, Dervenis C, et al. Classification of acute pancreatitis 2012: revision of Atlanta classification and definitions by international consensus. *Gut.* 2013;62:102–11, <http://dx.doi.org/10.1136/gutjnl-2012-302779>.
- Pezzilli R, Zerbi A, Campa D, et al. Consensus guideline on severe acute pancreatitis. *Dig Liver Dis.* 2015;47:532–43, <http://dx.doi.org/10.1016/j.dld.2015.03.022>.
- Worhunsky DJ, Qadan M, Dua MM, et al. Laparoscopic transgastric necrosectomy for the management of pancreatic necrosis. *J Am Coll Surg.* 2014;219:735–43, <http://dx.doi.org/10.1016/j.jamcollsurg.2014.04.012>.
- Barreiro-Domínguez EM, Zorrilla-Montero C, Ortiz-Navarro M. Test del verde de indocianina: ¿es realmente útil en cirugía de colon y recto? *Arch Coloproctol.* 2020;3:6–40, [http://dx.doi.org/10.26754/ojs\\_arcol/archcolo.202024567](http://dx.doi.org/10.26754/ojs_arcol/archcolo.202024567).
- Koong JK, Ng GH, Ramayah K, et al. Early identification of the critical view of safety in laparoscopic cholecystectomy using indocyanine green fluorescence cholangiography: a randomized controlled study. *Asian J Surg.* 2021;44:537–43, <http://dx.doi.org/10.1016/j.asjsur.2020.11.002>.
- Jao ML, Wang YY, Wong HP, et al. Intracholecystic administration of indocyanine green for fluorescent cholangiography during laparoscopic cholecystectomy—a two-case report. *Int J Surg Case Rep.* 2020;68:193–7, <http://dx.doi.org/10.1016/j.ijscr.2020.02.054>.
- Dip F, LoMenzo E, Sarotto L, et al. Randomized trial of near-infrared incisionless fluorescent cholangiography. *Ann Surg.* 2019;270:992–9, <http://dx.doi.org/10.1097/SLA.0000000000003178>.

R.D. Brito-Carmona\*, A. Cuendis-Velázquez, A.F. Chávez-Hernández, A.D. Galván-Cruz, L.E. Cárdenas-Lailson

*Departamento de Cirugía General y Endoscópica, Hospital General Dr. Manuel Gea González, Mexico City, Mexico*

\* Corresponding author. Dirección: Calz. de Tlalpan 4800, Belisario Domínguez Secc 16, Tlalpan, 14080 Mexico City, Mexico. Tel.: 5543152027.

E-mail address: [ronniedamian@hotmail.com](mailto:ronniedamian@hotmail.com)

(R.D. Brito-Carmona).

2255-534X/ © 2022 Asociación Mexicana de Gastroenterología.

Published by Masson Doyma México S.A. This is an open access article under the CC BY-NC-ND license (<http://creativecommons.org/licenses/by-nc-nd/4.0/>).

## Is intestinal diverticulosis a risk factor in video capsule endoscopy? ☆

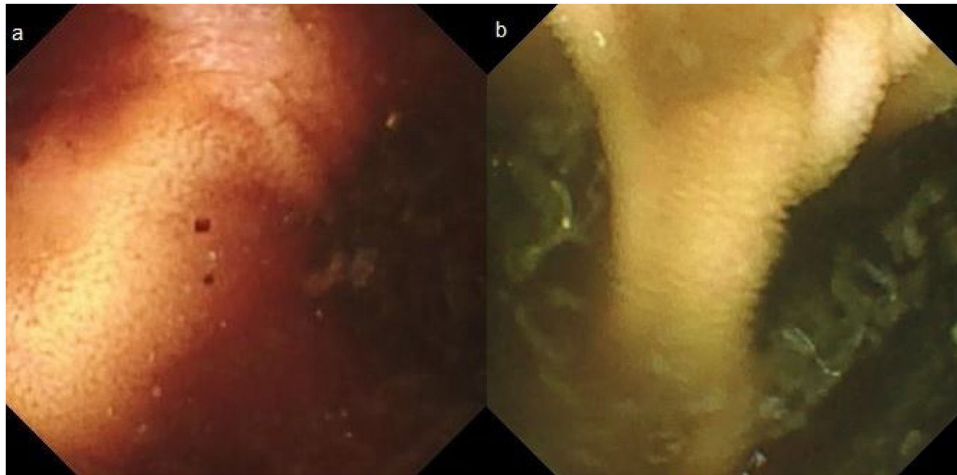


### ¿Es la diverticulosis intestinal un factor de riesgo para la cápsula endoscópica?

We present herein two cases: case 1 is a 71-year-old man who sought medical attention because of melanic stools. Complete blood count results were hemoglobin of 11.7 g/dl (previously normal) and urea of 104 mg/dl. After hemo-

dynamic stabilization, upper endoscopy and colonoscopy were performed, finding no lesions. Capsule endoscopy (CE) revealed active bleeding in the jejunum, but its cause could not be visualized. The video capsule remained at the site, with an abundant content of blood, and could not advance. A double-lumen image (Fig. 1a) and atrophic mucosa with no villi were shown on the digital photos, suggesting a small bowel diverticulum. Plain abdominal x-ray confirmed that the video capsule was still in the intestine. The patient reported having no clinical symptoms of obstruction and the bleeding was self-limited. Five days after undergoing the CE, the patient again presented with melanic stools and hemodynamic instability. Abdominal computed tomography angiography (CTA) confirmed bleeding in the 4 cm jejunal diverticulum that was retaining the video capsule. Laparotomy was performed, and a jejunal segment with

☆ Please cite this article as: Díaz-Alcázar MM, Aguilar-Cruz I. ¿Es la diverticulosis intestinal un factor de riesgo para la cápsula endoscópica? *Rev Gastroenterol Méx.* 2022;87:390–392.

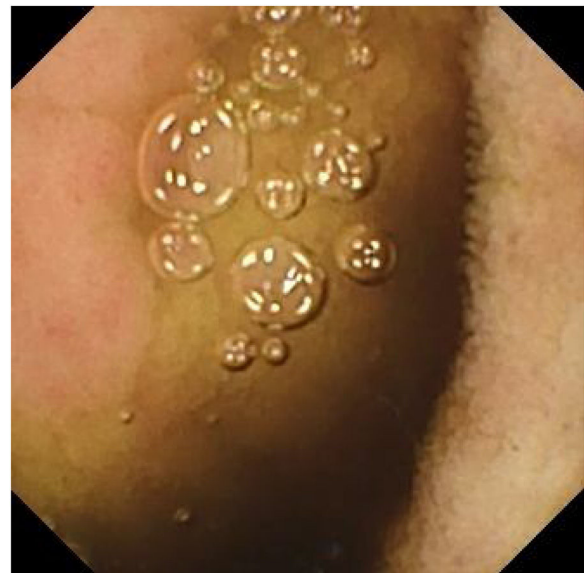


**Figure 1** Digital photos from the capsule endoscopy showing a double-lumen image consistent with a small bowel diverticulum (a and b).

large diverticula, one of which was retaining the video capsule, was resected. Case 2 corresponds to an 87-year-old man who sought medical attention due to hematochezia. Complete blood count results were hemoglobin of 9.9 g/dl. Colonoscopy revealed diverticular disease of the left colon, with no signs of bleeding, and upper endoscopy was normal. CE was performed because of the persistence of bleeding that required transfusion (15 units of red blood cells). The video capsule remained in the jejunum more than 19 h after the study, with no signs of bleeding in the segment examined. Digital photos showed a double-lumen image (Fig. 1b) and mucosa with no villi (Fig. 2), suggesting a jejunal diverticulum, albeit the abundant non-hematic intestinal content did not permit clear visualization. The patient did not present with signs of obstruction. Given the active bleeding, the evaluation of the patient was completed with a CTA, finding a 6 cm jejunal diverticulum and active bleeding in the terminal jejunum and ileum. The video capsule was confirmed to have advanced into the transverse colon, and later, the bleeding point was percutaneously embolized.

CE is a safe procedure, with an incidence of complications below 1.5%. The main complication is video capsule retention, the risk of which is higher in patients with Crohn's disease, anti-inflammatory drug use, intestinal tumors, radiation enteritis, or previous abdominal surgery<sup>1–4</sup>. A retention risk of up to 8.2% has been described in patients with Crohn's disease<sup>4</sup>. The arbitrary definition of retention is when the video capsule is identified in an abdominal imaging study, 14 days or longer after having been swallowed.<sup>4</sup> The majority of cases are asymptomatic and resolved conservatively. Unless there is high suspicion of a malignant etiology, conservative treatment of video capsule retention is recommended<sup>2,4</sup>. A published case report and literature review described a patient with video capsule retention for 4.5 years; it was finally retrieved endoscopically<sup>5</sup>.

In former clinical practice guidelines, diverticulosis of the small bowel and colonic diverticulosis were considered relative contraindications for CE<sup>1,6</sup>. However, there are few published cases of retention in that context<sup>2</sup>, and so current guidelines do not include them as contraindications<sup>3</sup>. Two cases were described herein, in which video capsule



**Figure 2** Digital photo from the capsule endoscopy showing an area of mucosa with no villi (to the left of the image) that could correspond to the wall of an intestinal diverticulum.

advancement was hindered by the presence of diverticula in the small bowel. In the first case, the capsule remained in the intestine for 5 days. It was then surgically retrieved, albeit the decision to operate was made, more with respect to the gastrointestinal bleeding than to the capsule retention. In the second case, even though capsule advancement was slower than expected, it spontaneously reached the colon. Nevertheless, our case series was small. Therefore, a larger number of cases and greater scientific evidence is needed to establish whether small bowel diverticula are a risk factor for incomplete examination of the small bowel and possible video capsule retention in CE.

### Ethical considerations

The authors declare that:

Informed consent was requested from the patients to receive treatment or participate in the research described.

The present work meets the current bioethical research regulations and was approved by the ethics committee of the *Hospital Universitario Clínico San Cecilio*.

This article contains no personal information that can identify the patients.

No experiments were conducted on animals or humans.

## Financial disclosure

No financial support was received in relation to this article.

## Conflict of interest

The authors declare that there is no conflict of interest.

## References

- Giday SA, Pickett-Blakely OE, Buscaglia JM, et al. Capsule retention in a patient with small-bowel diverticulosis. *Gastrointest Endosc*. 2009;69:384–6, <http://dx.doi.org/10.1016/j.gie.2008.03.1085>.
- Liao Z, Gao R, Xu C, et al. Indications and detection, completion, and retention rates of small-bowel capsule endoscopy: a systematic review. *Gastrointest Endosc*. 2010;71:280–6, <http://dx.doi.org/10.1016/j.gie.2009.09.031>.
- Courcoutsakis N, Pitiakoudis M, Mimidis K, et al. Capsule retention in a giant Meckel's diverticulum containing multiple enteroliths. *Endoscopy*. 2011;43:e308–9, <http://dx.doi.org/10.1055/s-0030-1256641>.
- Rondonotti E, Spada C, Adler S, et al. Small-bowel capsule endoscopy and device-assisted enteroscopy for diagnosis and treatment of small-bowel disorders: European Society of Gastrointestinal Endoscopy (ESGE) technical review. *Endoscopy*. 2018;50:423–46, <http://dx.doi.org/10.1055/a-0576-0566>.
- Bhattarai M, Bansal P, Khan Y. Longest duration of retention of video capsule: a case report and literature review. *World J Gastrointest Endosc*. 2013;5:352–5, <http://dx.doi.org/10.4253/wjge.v5.i7.352>.
- Biondi A, Persiani R, Vigorita V, et al. Education and imaging: gastrointestinal: videocapsule retention: rationale for surgical indication. *J Gastroenterol Hepatol*. 2011;26:608, <http://dx.doi.org/10.1111/j.1440-1746.2011.06618.x>.

M.M. Díaz-Alcázar<sup>a,\*</sup>, I. Aguilar-Cruz<sup>b</sup>

<sup>a</sup> *UGC Aparato Digestivo, Hospital Universitario Clínico San Cecilio de Granada, Spain*

<sup>b</sup> *Servicio de Urgencias, Hospital Universitario Clínico San Cecilio de Granada, Spain*

\* Corresponding author at: Hospital Universitario Clínico San Cecilio de Granada, Avenida de la Investigación s/n, 18016 Granada, Spain.

*E-mail address:* [mmardiazalcazar@gmail.com](mailto:mmardiazalcazar@gmail.com) (M.M. Díaz-Alcázar).

2255-534X/ © 2022 Asociación Mexicana de Gastroenterología. Published by Masson Doyma México S.A. This is an open access article under the CC BY-NC-ND license (<http://creativecommons.org/licenses/by-nc-nd/4.0/>).

## Granulomatosis with polyangiitis (Wegener's granulomatosis) with gastrointestinal involvement: A case report<sup>☆</sup>



### Granulomatosis con poliangiitis (granulomatosis de Wegener) con involucro gastrointestinal: reporte de caso

Granulomatosis with polyangiitis (GPA), formerly known as Wegener's granulomatosis<sup>1,2</sup>, is a necrotizing vasculitis that affects the small vessels, with systemic granulomatous inflammation predominantly in the upper respiratory tract, lungs, and kidneys. It is associated with the presence of cytoplasmic anti-neutrophil cytoplasmic antibodies (c-ANCA) and anti-proteinase 3 (anti-PR3) antibodies<sup>1-3</sup>. Albeit infrequently, cases of GPA with gastrointestinal (GI) involvement have been reported at 5–11%<sup>1,2</sup>. The clinical manifestations vary from abdominal pain to massive bleeding and perforation<sup>3,4</sup>.

We present herein the case of a 57-year-old woman, with an unremarkable past medical history, that presented with constitutional symptoms and symmetrical polyarthralgia for two months, as well as bloody stools on three occasions, resulting in her seeking medical attention at the emergency department. Upon hospital admission, her vital signs were within normal parameters. Physical examination revealed abdominal pain in the hypogastrium, increased peristalsis, no signs of peritoneal irritation, joint inflammation in the wrists and ankles, and prolonged capillary refill time; the rest of the examination showed no alterations. Laboratory test results were hemoglobin 9 g/dL, leukocytes 13,220 cell/mm<sup>3</sup>, PMN 81.3%, creatinine 3.40 mg/dL, BUN 39.5 mg/dL, urea 84.6 mg/dL, creatinine clearance 14.6 mL/min, sodium 135 mmol/L, potassium 4.99 mmol/L, C-reactive protein 210 mg/dL; urinalysis: proteinuria 1.51 g/L, hemoglobinuria +++, >100 erythrocytes, 8–10 leukocytes per field, and negative urine culture. Non-contrasted abdominal computed axial tomography (CAT) scan identified wall thickening and edema of the gastric mucosa, and in the terminal ileum, with scant free fluid. Management was started with omeprazole and antibiotic therapy with linezolid and metronidazole. Upper GI endoscopy and colonoscopy were performed, observing a 5 mm ulcer in the antrum (Forrest III) and multiple small ulcerations, with fibrin and a cobblestone pattern, in the terminal ileum and cecum. Biopsy results reported a perivascular inflammatory infiltrate, fibrinous exudate, edema of the lamina propria, and no evidence of malignancy (Fig. 1).

<sup>☆</sup> Please cite this article as: Pérez-Macías JP, Rodarte-Shade M, Garza-García CA, Tueme-De la Peña D, Rodríguez-Guerra ML. Granulomatosis con poliangiitis (granulomatosis de Wegener) con involucro gastrointestinal: reporte de caso. *Rev Gastroenterol Méx*. 2022;87:392–394.